

<https://doi.org/10.17221/144/2017-VETMED>

B-cell chronic lymphocytic leukaemia in an African lion (*Panthera leo*)

R. MEOLI¹, C. ELEN¹, P. CAVICCHIO², M.C. TONNICCHIA², B. BIANCANI³, L. GALOSI⁴, G. ROSSI^{4*}

¹Experimental Zooprophyllactic Institute of Lazio and Tuscany “M. Aleandri”, Rome, Italy

²Zoological Society of Pistoia, Pistoia, Italy

³Park Oltremare, Riccione, Italy

⁴School of Biosciences and Veterinary Medicine, University of Camerino, Matelica, Italy

*Corresponding author: giacomo.rossi@unicam.it

ABSTRACT: A 15-year-old female African lion (*Panthera leo*) maintained at the Zoological Garden of Pistoia, Tuscany (Italy), showed signs of malaise, dyspnoea, tremors, pale mucous membranes and ataxia for two days prior to death. Complete blood count showed anaemia, thrombocytopaenia and severe lymphocytosis. At autopsy, the most relevant finding was severe, generalised splenomegaly. Histologically, high numbers of neoplastic lymphocytes diffusely infiltrated the spleen, liver, heart, pancreas, kidney and lungs. The lymphoid cells were positive for CD79a and negative for CD3 on immunohistochemistry. The histologic features of the neoplastic cells and their immunophenotype are consistent with B-cell lymphocytes. Based on surface membrane co-expression of immunoglobulin M and immunoglobulin D in most neoplastic cells, which indicated that they were naïve, antigen-inexperienced and mature circulating resting B-cells, and consistent with their appearance as small lymphocytes with high nuclear-to-cytoplasmic ratios, a diagnosis of B-cell chronic lymphocytic leukaemia was made.

Keywords: lymphocytosis; feline, neoplastic disease

Neoplasms of the haematopoietic system are commonly seen in domestic animals; malignant lymphomas have been extensively studied in domestic canids and felids, but there is limited information on malignant lymphomas in non-domestic animals (Gabor et al. 1998; Harrison et al. 2010).

Exotic felids in captivity, particularly African lions (*Panthera leo*), are rarely diagnosed with malignant lymphoma and only three cases of T-cell chronic lymphocytic leukaemia have been reported so far (Harrison et al. 2010). These animals were males and had weight loss, anaemia, lymphocytosis and splenomegaly. Although lymphomas in domestic felids have been associated with feline leukaemia virus and feline immunodeficiency virus, there is only one documented case of lymphoma in a captive African lion that was concurrently infected with feline lentivirus (Harrison et al. 2010; Helfand and Kisseberth 2010; Vezzali et al. 2010).

In veterinary medicine, as in humans, haematopoietic neoplasms are classified as myeloid or lymphoid on the basis of histogenesis and are divided into acute and chronic forms, based on clinical presentation and the proliferative rate of the neoplastic cell clone (Tordiffe et al. 2013). Acute leukaemias are clonal proliferations of a progenitor cell with limited differentiation; therefore, identification of cellular markers is often necessary for definitive identification of the cell of origin. In chronic leukaemias, neoplastic cells are terminally differentiated, and the cellular origin is more readily identifiable (Gabor et al. 1998). The primary laboratory finding in chronic lymphocytic leukaemia is leucocytosis caused by an absolute lymphocytosis. In domestic cats, lymphocyte counts varying from 36 000 to 250 000/l have been reported and haematological findings could include anaemia, thrombocytopaenia, neutropaenia and neutrophilia. Animals with thrombocytopaenia

<https://doi.org/10.17221/144/2017-VETMED>

are predisposed to haemorrhage owing to decreased platelet numbers and abnormal cell function (Valli et al. 2000).

Case description

We describe herein a case of B-cell chronic lymphocytic leukaemia in a 15-year-old female African lion (*Panthera leo*), maintained at the Zoological Garden of Pistoia, Tuscany (Italy). In October 2015, the lioness displayed signs of malaise, dyspnoea, tremors, pale mucus membranes and ataxia for two days. The lioness was anaesthetised with a combination of 500 mg of tiletamine and zolazepam (Zoletil[®], Virbac, France) with addition of 7 mg of detomidine (Domosedan[®], Pfizer, USA) for diagnostic evaluation. Full anaesthesia was reached 25 minutes after injection and lasted for one hour. Ultrasonographic examination of the abdomen revealed diffuse, uniform and severe splenomegaly. Complete blood cell count results were anaemia and severe lymphocytosis. Biochemical indicators were elevated concentrations of urea and alanine aminotransferase, while albumin and glucose concentrations were low (Table 1). ELISA tests for feline immunodeficiency virus, feline leukaemia virus (SNAP[®] FIV/FeLV Combo Plus Test, IDEXX, USA) and *Dirofilaria immitis* (SNAP[®] 4Dx[®] Test, IDEXX, USA) were negative. Two days after the investigation, the lioness died.

Pathological findings. An autopsy was performed at the Zoological Garden of Pistoia. Samples of various organs were fixed in 10% buffered formalin and sent for histologic examination at the Experimental Zooprophyllactic Institute of Lazio and Tuscany. The samples were embedded in paraffin, sectioned at 5 µm, and stained with haematoxylin-eosin (H&E). Immunohistochemistry was performed with CD3 (Dako, UK), CD79a (Dako, UK) and CD20 (thermo Fisher Scientific, USA) antibodies at a dilution of 1 : 600 to establish whether the neoplastic cells were of T- or B-cell origin. Furthermore, anti-immunoglobulin M (goat anti-cat IgM, Biorad, USA) and anti-immunoglobulin D (rabbit polyclonal anti-IgD, Zeta Corporation, USA) antibodies were both used at a dilution of 1 : 200 in immunohistochemistry staining to evaluate the state of eventual activation of the B-cells, necessary to make a more precise diagnosis of the neoplastic form. Positive immunohistochemical

Table 1. Haematological and biochemical values

Parameter	Value	Reference range*
Red blood count	4.5	6.05–9.99 × 10 ¹² /l
Haemoglobin	9.0	9.81–16.79 g/dl
Thrombocytes	60	120–430 × 10 ⁹ /l
White blood count	150.8	5.75–21.47 × 10 ⁹ /l
Lymphocytes	82.9	0.0–4.1 × 10 ⁹ /l
Monocytes	0.75	0.0–1.21 × 10 ⁹ /l
Alp	5	0.0–49.32 U/l
Alt	139.5	5.26–100.74 U/l
Urea	5.7	5.83–17.73 mmol/l
Creatinine	330	141.4–336.6 µmol/l
Total protein	78	64.0–86.1 g/l
Albumin	17	25.75–40.25 g/l
Globulin	60	29.33–54.67 g/l
Calcium	1.01	1.43–3.47 mmol/l
Phosphorus	6.8	5.5 mg/dl
Sodium	143	136.4–165.6 mmol/l
Glucose	15	122 mg/dl
Potassium	6.5	3.49–5.31 mmol/l

*Reference ranges were calculated using the International Species Information System (ISIS) database values (Teare 1999) for lions

controls included a normal feline lymph node. For negative controls, the primary antibodies were replaced with homologous non-immune sera.

The most relevant finding during gross examination was a severe generalised splenomegaly. The spleen had rounded edges, was dark purple and was very dense. It weighed 7.5 kg (nearly 20 times its normal size) and was 110 cm high × 50 cm long × 20 cm wide. Other findings included pale mucosae, pale kidneys, pulmonary congestion associated with areas of lung parenchyma consolidation, mild catarrhal enteritis and numerous ovarian cysts; a small mass of increased toughness was observed in uterus. All lymph nodes appeared normal.

Histologically, large numbers of neoplastic lymphocytes diffusely infiltrated the spleen, liver, heart, pancreas, kidney and lung. The most prominent infiltrates were seen in the spleen (60% involvement), concentrated in the red pulp, with atrophy of lymphoid follicles (Figure 1). Massive infiltration of neoplastic cells was observed in liver sinusoids and, to a lesser extent, between the cardiac muscle fibres and around the pancreatic acini. Neoplastic cells consisted of small atypical lymphoid cells (6.5/7.5 µm) with small nuclei (high nuclear-to-cytoplasm ratio), an absence of nucleoli and coarsely

<https://doi.org/10.17221/144/2017-VETMED>

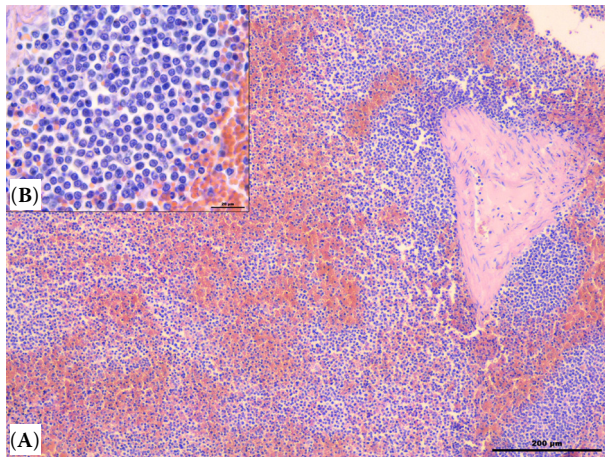


Figure 1. Spleen of an African lion with chronic lymphocytic leukaemia. (A) Neoplastic lymphocytes diffusely replacing most of the normal splenic cell population. Haematoxylin and eosin (H&E). Bar = 200 μ m. (B) Higher magnification; a detailed view of the characteristic features of atypical lymphocytes. Neoplastic cells consisted of small atypical lymphoid cells (6.5/7.5 μ m) with small nuclei (moderate N/C ratio), absence of nucleoli and coarsely aggregated chromatin and moderate amounts of pale cytoplasm. Haematoxylin and eosin (H&E). Bar = 20 μ m

aggregated chromatin and moderate amounts of pale cytoplasm. These cells, in many areas of organ infiltration, resembled normal lymphocytes, although slightly smaller. These neoplastic cells showed a low mitotic index (0 and 1 mitoses/HPF). In addition, membranoproliferative glomerulonephritis and chronic interstitial pneumonia, with areas of sclerosing alveolitis, were observed, along with lymphoplasmacytic enteritis and leiomyoma in the uterus. In lymph nodes, depletion of lymphoid follicles was observed. Immunohistochemically, most of the lymphoid cells showed characteristic cell membrane CD79a positivity and negativity for CD3. The B-cell marker CD20, used in this study, does not cross-react with African lion lymphocytes. Furthermore, B-cells showed a constant co-expression of immunoglobulin M and immunoglobulin D on their surface membranes, which usually marks naïve B-cells. Indeed, the view that B-cell chronic lymphocytic leukaemia (B-CLL) cells are antigen-naïve and resting but mature, is consistent with their appearance in tissue infiltrates, as small lymphocytes with a high nuclear-to-cytoplasmic ratio (Bennett et al. 1989). These immunohistochemistry findings were observed in all organs, with particular evidence in the spleen, where

90% of the neoplastic cells were positive for CD79a (Figure 2). The neoplastic lymphoid proliferation was classified using the current veterinary and human WHO classification of haematopoietic neoplasms (Valli et al. 2000; Vezzali et al. 2010).

In this case, the lioness showed typical signs of chronic lymphocytic leukaemia, including weight loss, splenomegaly, anaemia and marked lymphocytosis. Unfortunately, we were unable to obtain the bone marrow for evaluation. A massive infiltration of neoplastic cells was observed in liver sinusoids. Despite not having bone marrow, this favours classification as a leukaemia. Moreover, thrombocytopaenia indicates an important presence of neoplastic cells in the bone marrow. The massive infiltration of the spleen and other organs, and the features of the neoplastic cells, suggests that the lioness was affected by chronic lymphocytic leukaemia. The CD79a-positivity and CD3-negativity provide evidence that the leukaemia was primarily B-cell in origin. In particular, according to reports (Caligaris-Cappio et al. 1993), the accumulation in different organs of naïve, antigen-inexperienced, well-differentiated B lymphocytes that circulate in the resting state, is considered a typical mark of B-CLL.

DISCUSSION AND CONCLUSIONS

Malignant lymphoma is the most common malignant neoplasm diagnosed in domestic cats, while

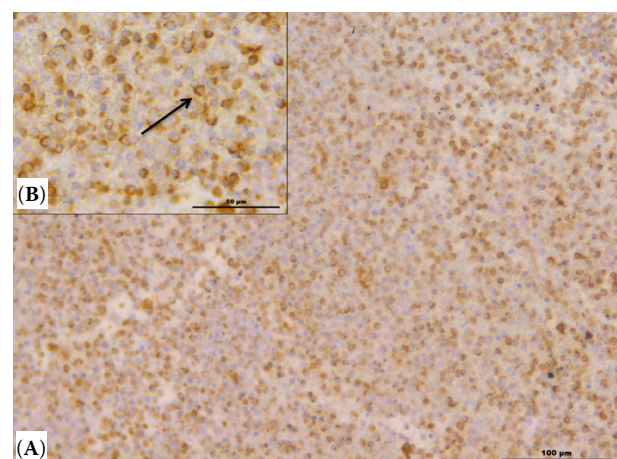


Figure 2. Spleen of an African lion with chronic lymphocytic leukaemia. (A) Neoplastic lymphocytes are immunoreactive for CD79a antibody. Bar = 100 μ m. (B) At higher magnification, characteristic cell membrane CD79a positivity was observed (arrow). Bar = 50 μ m

chronic lymphocytic leukaemia (CLL) is rare (Tebb et al. 2004). Exotic felids in captivity, particularly African lions, are rarely diagnosed with malignant lymphomas or CLL (Hruban et al. 1992; Owston et al. 2008; Valli 2010). Eleven cases of malignant lymphoma in African lions were described, and only one case was described as a diffuse large B-cell lymphoma (Harrison et al. 2010). The literature suggests that chronic lymphocytic leukaemia is most commonly of T-cell origin in exotic felids; the aetiology and pathogenesis in humans, dogs, cats and lions remains unknown. Neither feline leukaemia virus nor feline immunodeficiency virus, important causes of malignant lymphoma in domestic cats, are likely to be significant in the pathogenesis of malignant lymphoma in African lions (Poli et al. 1995; Callanan et al. 1996; Harrison et al. 2010).

Chronic lymphocytic leukaemia (CLL) is a common condition that typically affects geriatric human beings (Binet et al. 1981). In T-CLL cells, now called T-cell prolymphocytic leukaemia (Catovsky et al. 2001), a co-occurrence of high levels of CD3 antigen together with low levels of the B-cell surface antigens CD19, CD20 and CD23 is described (Moreau et al. 1997). The levels of the surface immunoglobulin CD20 were characteristically very low compared with those found on normal B-cells (Ginaldi et al. 1998).

The CD79a protein is present on the surface of B-cells throughout their life cycle and is also present in virtually all B-cell neoplasms; however, it is absent on all other healthy cells, making it a highly reliable marker for B-cells in immunohistochemistry. The B-cell marker CD20 is more commonly retained on mature B-cell lymphomas, so that the two are often used together in immunohistochemistry panels (Leong et al. 2003). In contrast, B-CLL cells typically express high levels of CD20, CD79a and surface Ig (Catovsky et al. 2001). Regarding surface Ig expression, B-CLL cells are generally naïve, antigen-inexperienced mature B lymphocytes that circulate in the resting state (Caligaris-Cappio et al. 1993), and their characteristic surface membrane co-expression of immunoglobulin M and immunoglobulin D, indicates their status as “virgin” B-cells (Coffman and Cohn 1977). Also, in the present case, B-CLL was diagnosed on the basis of ubiquitous B-cell marker CD79a immunohistochemistry expression, and surface membrane co-expression of immunoglobulin M and immunoglobulin D; unfortunately, the B-cell marker CD20 does not cross-react with lioness lymphocytes.

The numerous statistics published on CLL have revealed a certain number of prognostic factors. The importance of sex, age, the degree of peripheral lymphocytosis, the degree of associated anaemia or thrombocytopaenia, cutaneous manifestations, signs of inflammation and the onset of a sarcoma have all been stressed but it has not been possible to determine the relative importance of each of these (Binet et al. 1981). In humans, CLL is a neoplasm composed of monomorphic small B lymphocytes in the peripheral blood, bone marrow, spleen and lymph nodes that form proliferation centres in tissue infiltrates (Helfand and Kisseberth 2010). In CLL, B-cells exhibit uncontrolled proliferation and accumulate in the bone marrow and blood, crowding out healthy red or white blood cells and platelets. Asymptomatic people are often diagnosed after lymphocytosis is noted in a routine complete blood cell count; a marrow aspirate and biopsy generally are not required for the diagnosis (Hallek et al. 2008).

CLL in cats, where the disease appears most often, is characterised by small cells with round nuclei typically 1 to 1.5 red blood count in diameter with a very narrow rim of cytoplasm. Leukaemia would be expected to involve multiple tissues and in those interpreted to be true leukaemia, both acute lymphocytic leukaemia and CLL were more likely widely distributed, which attests to the utility of liver aspiration as an adjunct to examination of blood and marrow in the diagnosis of leukaemia (Vezzali et al. 2010).

Although CLL is a systemic disease, collections of pale cells known as proliferation centres, which are newly formed structures, and have not been described in reactive lymphadenitis or other lymphoproliferative conditions, can be found. The cells in these collections are also malignant cells but are somewhat larger and mitotically active. In the current case, no lymph node involvement was observed, like in domestic cats, and the lioness was negative for feline leukaemia virus and feline immunodeficiency virus; therefore, the aetiology of the leukaemia is unknown.

To our knowledge, this is the first case of B-cell chronic lymphocytic leukaemia reported in an African lion (*Panthera leo*).

Acknowledgements

The authors express their thanks to Professor Susan Cork from the University of Calgary, Canada,

<https://doi.org/10.17221/144/2017-VETMED>

for her valuable assistance in writing up this case, and Dr Paul Gatenby for his revision of the text.

REFERENCES

- Bennett JM, Catovsky D, Daniel MT, Flandrin G, Galton DA, Gralnick HR, Sultac C (1989): Proposals for the classification of chronic (mature) B and T lymphoid leukemias. French-American-British (FAB) Cooperative Group. *Journal of Clinical Pathology* 42, 567–584.
- Binet JL, Auquier A, Dighiero G, Chastang C, Piquet H, Goasquen J, Vaugier G, Potron G, Colona P, Oberling F, Thomas M, Tchernia G, Jacquillat C, Boivin P, Lesty C, Duault MT, Monconduit M, Belabbes S, Gremy F (1981): A new prognostic classification of chronic lymphocytic leukemia derived from a multivariate survival analysis. *Cancer* 48, 198–206.
- Caligaris-Cappio F, Gottardi D, Alfarano A, Stacchini A, Gregoret MG, Ghia P, Bertero MT, Novarino A, Bergui L (1993): The nature of the B lymphocyte in B-chronic lymphocytic leukemia. *Blood Cells* 19, 601–613.
- Callanan JJ, Jones BA, Irvine J, Willett BJ, McCandlish IA, Jarrett O (1996): Histologic classification and immunophenotype of lymphosarcomas in cats with naturally and experimentally acquired feline immunodeficiency virus infection. *Veterinary Pathology* 33, 264–272.
- Catovsky D, Ralfkiaer E, Muller-Hermelink HK (2001): T-cell prolymphocytic leukaemia. In: Jaffe ES, Harris NL, Stein H, Vardiman JW (eds): *World Health Organization Classification of Tumours: Pathology and Genetics of Tumours of Haematopoietic and Lymphoid Tissues*. Lyon, France: IARC Press. 195–196.
- Coffman RL, Cohn M (1977): The class of surface immunoglobulin on virgin and memory B lymphocytes. *The Journal of Immunology* 118, 1806–1815.
- Gabor LJ, Malik R, Canfield PJ (1998): Clinical and anatomical features of lymphosarcoma in 118 cats. *Australian Veterinary Journal* 76, 725–732.
- Ginaldi L, De Martinis M, Matutes E, Farahat N, Morilla R, Catovsky D (1998): Levels of expression of CD19 and CD20 in chronic B cell leukaemias. *Journal of Clinical Pathology* 51, 364–369.
- Hallek M, Cheson BD, Catovsky D, Caligaris-Cappio F, Dighiero G, Dohner H, Hillmen P, Keating MJ, Montserrat E, Rai KR, Kipps TJ (2008): Guidelines for the diagnosis and treatment of chronic lymphocytic leukemia: a report from the International Workshop on Chronic Lymphocytic Leukemia updating the National Cancer Institute-Working Group 1996 guidelines. *Blood* 15, 5446–5456.
- Harrison TM, McKnight CA, Sikarskie JG, Kitchell BE, Garner MM, Raymond JT, Fitzgerald SD, Valli VE, Agnew D, Kiupel M (2010): Malignant lymphoma in African lions (*Panthera leo*). *Veterinary Pathology* 47, 952–957.
- Helfand SC, Kisseberth WC (2010): General features of leukemia and lymphoma. In: Weiss DJ, Wardrop KJ (eds): *Schalm's Veterinary Hematology*. 6th edn. Wiley-Blackwell, Ames. 455–466.
- Hruban Z, Vardiman J, Meehan T, Frye F, Carter WE (1992): Haematopoietic malignancies in zoo animals. *Journal of Comparative Pathology* 106, 15–24.
- Leong ASY, Cooper K, Leong F, Joel WM (eds) (2003): *Manual of Diagnostic Cytology*. 2nd edn. Greenwich Medical Media. 83–84.
- Moreau EJ, Matutes E, A'Hern RP, Morilla AM, Morilla RM, Owusu-Ankomah KA, Seon BK, Catovsky D (1997): Improvement of the chronic lymphocytic leukemia scoring system with the monoclonal antibody SN8 (CD79b). *American Journal of Clinical Pathology* 108, 378–382.
- Owston MA, Ramsay EC, Rotstein DS (2008): Neoplasia in felids at the Knoxville Zoological Gardens, 1979–2003. *Journal of Zoo and Wildlife Medicine* 39, 608–613.
- Poli A, Abramo F, Cavicchio P, Bandecchi P, Ghepardi E, Pistello M (1995): Lentivirus infection in an African lion: A clinical, pathologic and virologic study. *Journal of Wildlife Disease* 31, 70–74.
- Teare AJ (ed.) (1999): *International Species Information System: Physiological Data Reference Values*. Apple Valley.
- Tebb AJ, Cave T, Barron R, Brown AL, Martineau HM, Willett BJ, Hosie MJ (2004): Diagnosis and management of B cell chronic lymphocytic leukaemia in a cat. *Veterinary Record* 154, 430–433.
- Tordiffe ASW, Cassel N, Lane EP, Reyers F (2013): Multiple myeloma in a captive lion (*Panthera leo*). *Journal of the South African Veterinary Association* 84, 1–5.
- Valli VE (2010): B-cell Tumors. In: Weiss DJ, Wardrop KJ (eds): *Schalm's Veterinary Hematology*. 6th edn. Wiley-Blackwell, Ames. 491–585.
- Valli VE, Jacobs RM, Norris A, Couto CG, Morrison WB, McCaw D, Cotter S, Ogilvie G, Moore A (2000): The histologic classification of 602 cases of lymphoproliferative disease using the National Cancer Institute Working Formulation. *Veterinary Journal of Diagnostic Investigation* 12, 295–306.
- Vezzali E, Parodi AL, Marcato PS, Bettini G (2010): Histopathologic classification of 171 cases of canine and feline non-Hodgkin lymphoma according to the WHO. *Veterinary and Comparative Oncology* 8, 38–49.

Received: November 16, 2017

Accepted after corrections: May 30, 2018