

Trans-Urethral Ultrasound Guided Bladder Biopsy with Flexible Endoscopic Forcep in a Dog

Cerquetella Matteo, Fruganti Alessandro, Laus Fulvio, Dini Fabrizio and Tambella Adolfo Maria
School of Veterinary Medical Sciences, University of Camerino, Via Circonvallazione 93/95,
62024-Matelica (MC), Italy

Abstract: In the present study the case of a dog periodically presenting hematuria is reported. The patient was affected by a cystitis and the final diagnosis was obtained thanks to histopathology performed on biopsy specimens sampled using a flexible endoscopic biopsy forcep passed through the urethra to the bladder under ultrasound guidance.

Key words: Flexible endoscopic biopsy forcep, ultrasound guided biopsy, cystitis, bladder neoplasia, diagnosis, Italy

INTRODUCTION

Cystitis in dogs, usually does not represent a diagnostic challenge; direct clinical examination, hematologic evaluations, urinalysis, abdominal radiographs and ultrasonography represent minimally invasive diagnostic methods, usually effective at that aim. Cystoscopy could be of aid to better identify some anatomic defects and as a mean to obtain biopsy samples of the mucosa or of possibly present neoformations; nevertheless such diagnostic tool require general anesthesia (Adams and Syme, 2010) and an equipment not always available in all facilities.

Ultrasonographically, the wall thickness of a normal bladder is variable depending on the repletion state: thicker when empty and more thin when replete (Sutherland-Smith, 2008) while in case of cystitis it is usually characterized by a thickening of the wall, generally hypoechoic. Mean wall thickness of a normal minimally distended bladder in the dog is about 2.3 mm (Nyland *et al.*, 2002a; Sutherland-Smith, 2008). Rarely, cystitis may also appear as polypoid neoformations protruding into the lumen as well as neoplastic formations could invade large portions of the bladder wall; biopsy (surgical, cystoscopic and ultrasound-guided suction biopsy) is usually necessary to differentiate the two conditions (Sutherland-Smith, 2008; Chun and Garrett, 2010). Also cytology (urinary sediment, traumatic catheterization, cytology brush, percutaneous fine-needle aspiration) could be of aid even if the percutaneous approach must be considered very carefully because of

the risk of possible tumor cells spreading while retracting the needle (Nyland *et al.*, 2002b; Sutherland-Smith, 2008; Chun and Garrett, 2010).

Considering that to obtain a biopsy sample of the bladder, depending on the procedure chosen, it is often necessary a general anesthesia or at least a heavy sedation (Sutherland-Smith, 2008) and that between surgery, cystoscopy and ultrasound-guided suction biopsy, the first is rather invasive and the second necessitates of a specific equipment, the ultrasound-guided suction biopsy represent a good option. It does not necessitate of expensive/specialized equipment and has been reported to be used also in unsedated animals (Lamb *et al.*, 1996).

The aim of the present study is to describe a possible alternative method to obtain bladder biopsy samples, using a flexible endoscopic biopsy forcep passed through the urethra to the bladder under ultrasound guidance.

CLINICAL CASE DESCRIPTION

A 7 years old, female, mixed-breed dog of 45 kg of weight was presenting from about 1 month, a roundish skin lesion in the median lumbosacral area secreting a small amount of sero-purulent material. The private veterinary practitioner, once identified the problem in a secreting fistula, decided to refer the case to the Veterinary Teaching Hospital (VTH), School of Veterinary Medical Science, University of Camerino, for further clinical investigation. About 6 years before the dog underwent to surgery, at the VTH, for a fracture of the

seventh lumbar vertebra with lower motor neuron syndrome. In that case a lumbosacral laminectomy associated with a segmental spine fixation from L6 to S1 by mean of cortical screws and polymethylmethacrylate bone cement was performed. Being the fistula close to the previous surgical area, a connection among the two disorders might be possible despite the considerable time elapsed from the spinal surgery without any problem referred by the owner.

At admission, complete general, neurologic and orthopedic examinations were performed. His gait was satisfactory and no major neurological or orthopedic signs were found. The area around the fistula was slightly depressed and the dog showed no particular signs of pain during the deep palpation of the area. Fistula's probing allowed to reach about 3 cm of depth from the skin in direction of the spine. A direct radiographic study of lumbosacral spine was then performed in ventrodorsal and laterolateral orthogonal projections. The fracture of the seventh lumbar vertebra resulted to be completely healed and no radiographic signs of spinal osteomyelitis were identified. The implant was in situ and no signs of migration or loss of integrity were apparent. A fistulography was then performed introducing 8 mL of iomeprol (300 mg mL⁻¹) inside the duct. The channel of the fistula ended its career in the subcutaneous area, approximately 2 cm dorsally to the implant area. The complete blood count (cbc) revealed a total number of $13.3 \times 10^3 \mu\text{L}^{-1}$ white blood cells, $7.45 \times 10^6 \mu\text{L}^{-1}$ erythrocytes and $309 \times 10^3 \mu\text{L}^{-1}$ platelets. Serum biochemical analysis showed parameters within the normal ranges.

Being unable to the home treatment, the owner expressly asked to hospitalize the dog to practice the appropriate therapy. The dog was hospitalized and underwent to accurate, twice a day, disinfection of the fistula channel; the antibiotic-therapy already started by the private veterinary practitioner (clindamycin 10 mg kg⁻¹ twice a day, orally) was continued.

During the hospitalization, the fistula gradually improved and completely healed at the 15th day. While hospitalized the dog showed also a massive hematuria; once contacted, the owner, reported that from time to time the animal was showing such disorder, periodically treated with antibiotics leading only to temporary resolution of clinical signs. The standard physico-chemical urinalysis revealed a reddish-brown color, cloudy appearance, high proteinuria, light glycosuria and bilirubinuria, specific gravity 1.030 and pH 8. Furthermore, the microscopic visualization of the urinary sediment

revealed a massive presence of leukocytes, erythrocytes, epithelial transition cells and struvite crystals, leading to consider a cystitis. The antibiotic therapy was then integrated with urine acidifying drugs (methionine and ammonium chloride) and with a specific diet for the urinary tract disease (struvite uroliths dissolution).

A second cbc performed at the 3rd day of hospitalization pointed out a marked leukocytosis ($32.8 \times 10^3 \mu\text{L}^{-1}$) with neutrophilia ($25.584 \times 10^3 \mu\text{L}^{-1}$, 78%). Based on urinalysis it was performed an ultrasonography (MyLab™ 30 Vet-Esaote, provided of a multifrequency microconvex probe 5.0-8.0 MHz) of the urinary bladder in order to both visualize the bladder wall/content and to take a sample of urine by ultrasound guided cystocentesis, to submit for bacteriological examination with related antibiotic susceptibility test.

The bladder, only partially replete, showed the presence of a rather diffuse thickening of the wall, reaching in a point a maximum value of 2.71 cm; the bladder wall was mostly hypoechoic but also inhomogeneous in some points while within it, it was present a moderately echogenic sludge (Fig. 1). The centesis was performed at the ventral point of minimum thickness. The bacteriological examination showed the presence of multi-resistant bacteria such as *Enterococcus*

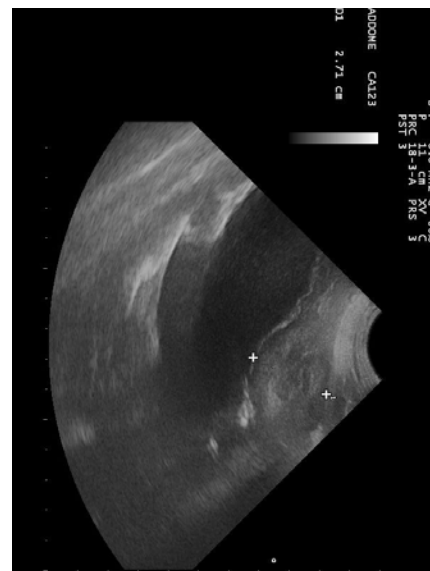


Fig. 1: Ultrasonographic transverse scan of the bladder; it is possible to observe the diffuse and also in some point inhomogeneous (see between cursors), marked thickening of the wall. Suspended material is also present inside the bladder




Fig. 2: Flexible endoscopic biopsy forcep used for the biopsy samplings; in the box the close up view of the distal tip of the forcep

sp. (sensitive only to amikacin and doxycycline) and *E. coli* (sensitive only to doxycycline), on that basis a therapy with doxycycline was undertaken, interrupting clindamycin administration.

Even if the thickening was quite diffuse and not focal, leading to consider primarily a cystitis in the differential list, the researchers could not rule out the presence of a neoplasia based neither on the ultrasonographic appearance nor on urinary sediment; for this reason it was decided to take a sample of the bladder mucosa/wall. After having decided of avoiding the execution of a percutaneous fine-needle aspiration of the wall because of the possible risk of tumor spreading in case of the presence of a neoplasia diffusely invading the bladder wall (e.g., transitional cell carcinoma), it was decided to perform a direct biopsy of the mucosa. In order to minimize the invasiveness of the procedure, the surgical option was discarded and instead of performing a cystoscopy or an ultrasound-guided suction biopsy, it was used a flexible endoscopic biopsy forcep (Fig. 2) 1.8 mm, length 180 cm, 3 mm serrated oval jaws), passed through the urethra and guided ultrasonographically inside the bladder. The dog was sedated with medetomidine hydrochloride ($10 \mu\text{g kg}^{-1}$) and tramadol (2 mg kg^{-1}) intramuscularly and then the biopsy forcep gently entered inside the urethra and pushed till reaching the lumen of the bladder. There, it was further driven close to the cranial portion of the bladder (the thickest and more inhomogeneous one) and a biopsy, under ultrasound guidance was performed. Totally, two biopsies were sampled.

Histopathology performed on the biopsy samples, both of diagnostic quality, confirmed the presence of a chronic-active parenchymatous cystitis with severe mucosal damage. The bladder wall fragments were

strongly affected by a deep, destructive, inflammatory process with infiltration of polymorphonuclear leukocytes from the muscularis layer. In the submucosal connective tissue, associated with the infiltration of polymorphonuclear cells, several necrotic and calcified areas were also observed. The general appearance of the organ was partly fibrotic and sometimes hyperemic and edematous. Based on that achievement the researchers decided to administer prednisolone (1 mg kg^{-1} once a day, orally) for 1 week.

The patient was discharged after 30 days suggesting to continue a specific diet (reduction of incidence and recurrence of struvite uroliths). At discharge, the urine did not show macroscopic hematuria anymore, the pH decreased to 6.0 and the microscopic urinary sediment revealed only occasional epithelial transition cells and struvite crystals. The ultrasonographic appearance of the bladder wall appeared almost unchanged.

DISCUSSION

To exactly differentiate a cystitis from a bladder wall neoplasia is usually necessary to perform a biopsy. Cytology could be of aid but in case of negative response a more thorough investigation including histopathology, is required.

In the case described, cytology performed on urinary sediment was indicative of cystitis but the peculiar ultrasonographic appearance of the bladder wall even if compatible with such diagnosis, still left the doubt that it could be affected by a neoplasia. In order to be sure of the diagnosis the researchers decided to perform a biopsy instead of a second cytological sampling (e.g., using cytology brush).

The various biopsy options differ in term of invasiveness and equipment required. The surgical biopsy of the bladder is the most invasive but provides larger and full-thickness samples and above all it is possible to directly visualize the area to be sampled; it can be performed laparotomically or laparoscopically (Stone *et al.*, 1996; Nyland *et al.*, 2002b; Barnes *et al.*, 2006).

Cystoscopy is also a good option even if it has to be considered that more than one cystoscope is necessary depending on patient weight. In female dogs rigid endoscopes with an Outer Diameter (OD) ranging from 1.9-4 mm and a length from 18-30 cm are usually used while in male a flexible endoscope is necessary (Rawlings, 2011). Flexible tools are available with different OD and length; depending on the patient size, it should be used the largest endoscope as possible, allowing the use of flexible biopsy instruments able to provide samples large

enough to be diagnostic. Furthermore, the higher the caliber of the instrument the greater the possibility of having an adjustable tip (usually one or two directions). Finally the use of a catheter is considered a simple and convenient technique. It is performed using a urinary catheter and placing its distal side holes close to the neoformation that has to be sampled with a syringe, a negative pressure is then applied and maintained while withdrawing the catheter. A certain skill of the operator is necessary to exactly place the catheter and only mucosal lesion can be sampled with this technique (Lamb *et al.*, 1996).

In the present study the researchers investigated the possibility of using a flexible biopsy forcep instead of the suction biopsy to obtain a bladder sample, always under ultrasonographic guidance. In the case described, the bladder wall was diffusely thickened even if in a non-uniform way.

Furthermore, in some point the wall had an heterogeneous appearance; for this reason it has been decided to sample the mucosa/wall in order to be sure that the problem of the patient was a cystitis as suggested from urinalysis and not a neoplasia. The possibility of using a flexible biopsy forcep allowed its easy positioning close to area that the operator wanted to sample as well as a quick sampling.

Moreover, this technique also allowed the operator to monitor precisely the site of the biopsy obtaining a sample deep enough to achieve the diagnosis. Difficulties in the positioning of the forcep may however be encountered due to the limited directionality of the forcep with this technique.

CONCLUSION

Finally, in the case described, the researchers decided to sedate the patient but it is possible to speculate that this technique may be applicable also in awake patients.

REFERENCES

- Adams, L.G. and H.M. Syme, 2010. Canine Ureteral and Lower Urinary Tract Diseases. In: Textbook of Veterinary Internal Medicine, Ettinger, S.J. and E.C. Feldman (Eds.). 7th Ed., Vol. 2, Saunders Elsevier, St. Louis, USA., pp: 2086-2115.
- Barnes, R.F., C.L. Geenfield, D.J. Schaeffer, J. Landolfi and J. Andrews, 2006. Comparison of biopsy samples obtained using standard endoscopic instruments and the harmonic scalpel during laparoscopic and laparoscopic-assisted surgery in normal dogs. *Vet. Surg.*, 35: 243-251.
- Chun, R. and L.D. Garrett, 2010. Urogenital and Mammary Gland Tumors. In: Textbook of Veterinary Internal Medicine, Ettinger, S.J. and E.C. Feldman (Eds.). 7th Ed., Vol. 2, Saunders Elsevier, St. Louis, USA., pp: 2208-2212.
- Lamb, C.R., N.D. Trower and S.P. Gregory, 1996. Ultrasound guided catheter biopsy of the lower urinary tract: Technique and results in dogs. *J. Small Anim. Pract.*, 37: 413-416.
- Nyland, T.G., J.S. Mattoon and E.J. Herrgesell, 2002b. Urinary Tract. In: Small Animal Diagnostic Ultrasound, Nyland, T.G. and J.S. Mattoon (Eds.). 2nd Edn., Saunders, Philadelphia, PA USA., pp: 158-195.
- Nyland, T.G., S.T. Wallach and E.R. Wisner, 2002a. Needle-tract implantation following us-guided fine-needle aspiration biopsy of transitional cell carcinoma of the bladder, urethra, and prostate. *Vet. Radiol. Ultrasound*, 43: 50-53.
- Rawlings, C.A., 2011. Cistoscopy. In: Small Animal Endoscopy, Tams, T.R. and C.A. Rawlings (Eds.). 3rd Ed., Elsevier Mosby, St. Louis, USA., pp: 507-554.
- Stone, E.A., T.F. George, S.D. Gilson and R.L. Page, 1996. Partial cystectomy for urinary bladder neoplasia: Surgical technique and outcome in 11 dogs. *J. Small Anim. Practice*, 37: 480-485.
- Sutherland-Smith, J., 2008. Bladder and Urethra. In: Atlas of Small Animal Ultrasonography, Penninck, D., M.A. d'Anjou (Eds.). Blackwell Publishing, Ames, USA., pp: 365-383.